

IMAGING MODALITIES IN OVARIAN CANCER: ROLE IN PATIENT MANAGEMENT

Solopova A.E.¹, Dadak C.², Makatsaria A.D.³,
Kolesnikova O.G.³, Sukhih G.T.¹

Purpose. To analyze the data available in the modern scientific medical literature on contemporary aspects of the diagnosis, staging and differential treatment tactics in patients with epithelial ovarian cancer.

Materials and methods. Research method used in this article is the systematic analysis of the medical literature, including Pubmed and ClinicalTrials.gov.

Results. This article attempts to summarize the worldwide experience of modern medicine in management of epithelial ovarian cancer. The current version of the ovarian cancer classification is described. The possibilities of imaging techniques and their place in the staging are determined. The accurate criteria for tumor resectability assessment and the main treatment tactics are given in details. The possibilities of imaging methods in treatment control and monitoring treatment response are provided. The leading imaging modalities for recurrent disease evaluation are delineated.

Conclusion. Ovarian cancer is a serious diagnostic challenge in terms of differential diagnosis, staging and selection of optimal treatment strategy. Proper use of visualization modalities allows better management of primary and recurrent ovarian cancer. Moreover, it is necessary to conduct further investigations aimed at developing well-defined diagnostic protocols in monitoring during treatment in order to obtain response evaluation with minimal time delay.

Keywords: ovarian cancer, imaging modalities, staging, MRI, optimal cytoreduction, resectability assessment, treatment control.

Corresponding author: Solopova A.E., dr.solopova@mail.ru

For citation: Solopova A.E., Dadak C., Makatsaria A.D., Kolesnikova O.G., Sukhih G.T. *Imaging modalities in ovarian cancer: role in patients management. REJR 2018; 8(3):30-47. DOI:10.21569/2222-7415-2018-8-3-30-47.*

Статья получена: 29.06.18 Статья принята: 13.07.18

МЕТОДЫ ЛУЧЕВОЙ ДИАГНОСТИКИ ПРИ РАКЕ ЯИЧНИКОВ: РОЛЬ В ТАКТИКЕ ВЕДЕНИЯ ПАЦИЕНТОК

Солопова А.Е.¹, Дадак К.², Макацария А.Д.³,
Колесникова О.Г.³, Сухих Г.Т.¹

Цель. Систематический обзор данных, накопленных в современной научной медицинской литературе по вопросам актуальных проблем диагностики, стадирования и дифференцированной тактики лечения пациенток с эпителиальным раком яичника.

Материалы и методы. Метод исследования, использованный в данной статье, - это систематический анализ отечественных и зарубежных медицинских источников.

Результаты. В данной статье предпринята попытка обобщить опыт современной медицины в ведении эпителиального рака яичника. Приведена современная версия классификации рака яичников. Определены возможности и место методов лучевой диагностики в стадировании. Подробно описаны точные критерии для оценки резектабельности опухоли и основные методы лечения. Представлена перспектива использования методов визуализации в контроле лечения и мониторинге ответа на проводимую терапию. Описаны ведущие методы лучевой диагностики для определения рецидива

1 - ФГБУ "Национальный медицинский исследовательский центр акушерства, гинекологии и перинатологии им. ак. В.И. Кулакова" Минздрава России. г. Москва, Россия
2 - Венский медицинский университет. г. Вена, Австрия
3 - Сеченовский Университет. г. Москва, Россия

заболевания.

Заключение. Рак яичника представляет собой серьезную проблему с точки зрения дифференциальной диагностики, стадирования и выбора оптимального метода лечения. Надлежащее использование диагностических методов позволяет наилучшее ведение пациентов с первичным и рецидивирующим раком яичников. Более того, необходимы дальнейшие исследования, направленные на разработку четких диагностических протоколов в мониторинге специфического лечения, с целью получения оценки ответа опухоли с минимальным интервалом.

Ключевые слова: рак яичников, методы лучевой диагностики, стадирование, МРТ, оптимальная циторедукция, оценка резектабельности, контроль лечения.

Контактный автор: Солопова А.Е., dr.solopova@mail.ru

Для цитирования: Солопова А.Е., Дадак К., Макацария А.Д., Колесникова О.Г., Сухих Г.Т. Методы лучевой диагностики при раке яичника: роль в тактике ведения пациентов. *REJR* 2018; 8 (3):30-47. DOI:10.21569/2222-7415-2018-8-3-30-47.

Received: 29.06.18 Accepted: 13.07.18

Introduction.

According to national statistics, 14030 cases of ovarian cancer were registered in 2017 in the Russian Federation [1]. It represents 2.38% malignant neoplasms incidence in women. Ovarian cancer is the third most common malignancy of the female genital tract, occurring less frequently than cancers of the endometrium and cervix [1]. The average age of the cases in 2016 was 59 years (in 2006 — 58.3 years). During the past decade ovarian cancer incidence rate tends to increase and in 2016 incidence reached 17.81 cases per 100,000 women per year [2]. Obviously, the reason lies in the features of the sex and age pyramid of the Russian population: a high proportion of women over 50 years, when the incidence is maximal, as well as a low fertility rate. There is a spur increase in ovarian cancer incidence after the age of 40, taking maximum at 65-69 years (39,07 cases per 100,000 women per year) and then slowly decreases [2].

Ovarian cancer represents the seventh most common cause of cancer mortality in women in Russia [2]. Number of deaths from it in Russia in 2016 was 7 645, it makes 5,17% in common cancer mortality rate [2]. The mortality was 9.71 per 100,000 women per year. In the age group of 50-54 years ovarian cancer represents the second cause of cancer death (9.15%) after breast cancer. In the age category 55-59 years there has been a similar situation (7.96% of cancer death). There are different reasons of ovarian cancer-associated mortality. The main reason is its late detection, when the disease spreads throughout the pelvis and beyond it. Approximately 2/3 of patients are diagnosed at an advanced tumor stage with distant metastases (39% for stage III and 19.5% for stage IV) and only 39.4% of women have stage I-II [1]. According to statistics, cancer survival has got

better but for ovarian cancer it is only a slight improvement. Mortality of patients during the first year after the initial diagnosis in 2017 is 20.9 %. Positive dynamics in 10 recent years can be noted in Russia. Thus, in 2007 27.4% of ovarian cancer patients died in the first year. The 5-year survival rate is more than 60% [1]. It is better with the early-stage diagnosis and constitutes 80%. Conversely, the 5-year survival rate for women diagnosed with advanced stages disease is about 30% [1]. In this case, even with the help of additional chemotherapy and extensive surgery the possibility of tumor recurrence has high probability.

Lifetime risk for developing ovarian cancer is 1,22% [2]. The main factor associated with the highest increase in cancer risk is genetic predisposition which is present of BDCA1 or BRCA2 mutations [15]. Cancer in first-degree relative history, previous cancer diagnosis, nulliparity, postmenopausal status, lack of breastfeeding, lack of hormonal contraception use and endometriosis are commonly known as risk factors in ovarian cancer [15] [16]. Comparable data were published in USA. On the contrary, ovarian cancer incidence rate tends to decrease in the past years there [3]. The remaining indicators are comparable with domestic data [4] [5]. It is estimated that there will be 22,240 new ovarian cancer cases and 14,070 cancer deaths in 2018 in the USA [4].

At the moment it is known that the term «ovarian cancer» includes dissimilar cancer subtypes. This heterogeneous group differs in etiology, pathogenesis, prognosis and molecular pathology [5] [6] [7]; moreover, some of subtypes derives outside of the ovary [8] [9]. This review focuses on epithelial ovarian cancer as it is 90% of all ovarian cancers (5% accounts for germ cell and 5% for sex cord and stromal) [10]. According to the new WHO Classification of Ovarian Cancer there are seven

primary subtypes: serous, mucinous, seromucinous, endometrioid, clear-cell, Brenner tumors and undifferentiated carcinoma [11]. Approximately 35-40% of epithelial ovarian cancer accounts for serous carcinoma. This histologic subtype is usually diagnosed at late stages and has the largest contribution to ovarian cancer mortality [9] [12].

In addition to the WHO histological classification, a dualistic model of pathogenesis based on the latest advances in pathology and molecular biology has now been established. According to this theory, epithelial ovarian tumors are divided into carcinomas of type I and II.

Type I tumors include endometrioid, clear cell, seromucinous, low-grade serous, mucinous carcinomas and malignant Brenner tumors. This type is characterized by low malignant potential, long-term asymptomatic and is often diagnosed in the early stage of the tumor process [13]. As for molecular genetic feature presence of mutations in KRAS, BRAF, ERBB2, MAP, ERK, LTEN, PIK3CA, ARID1A is typical for this group of tumors. Moreover, type I has genetic stability. Carcinomas from this group develop from benign extra-ovarian foci that implant on the ovary and may undergo malignant transformation [14].

High-grade serous carcinomas, high-grade endometrioid, carcinosarcomas and undifferentiated carcinomas represent type II tumors [14]. The main molecular markers of this group are TP53 gene mutation and BRCA1/2 dysfunction [13]. Tumors of this type develop mainly from intraepithelial carcinoma of the fallopian tube and subsequently spread to the ovary and other extraovarian tissues [14].

Epithelial ovarian cancer has three degrees of malignancy: benign, malignant and borderline if tumor has all the features of malignant neoplasms except stromal invasion [15].

Staging.

According to the FIGO or TNM classifications ovarian cancer is staged surgically. Cancer staging is pivotal as it allows to predict patient outcome and to plan the most appropriate management of the disease. The First International Federation of Gynecology and Obstetrics (FIGO) ovarian cancer staging system was developed in 1973 and then was twice revised in 1988 and 2014 [17] [18]. The main purpose of 2014 review was to reflect cumulative data in understanding of the origin, biology, immunohistochemistry, genetics, histopathological features, pathogenesis, prognosis and response to the chemotherapy of EOC [7] [17] [19] [20]. The main changes are given in detail in the description of the stages.

Findings obtained during the operation are the main criteria for FIGO classification [15]. Surgery consists of several main steps such as total abdominal hysterectomy, bilateral salpingo-oophorectomy, removal of pelvic and para-aortic

lymph nodes and omentum with laparotomic access and multiple peritoneal biopsies throughout the pelvis and upper abdomen. Received material needed to be identify for histological grade and cytological type.

The principal difference between old and new variants of FIGO Classification is that in new version fallopian tube and primary peritoneal cancer are classified in association with ovarian cancer due to common origin. To date this cancers are no longer distinguished as separate diversities and in that way have the same staging [21].

Revised FIGO Classification

Stage I

At this stage ovarian cancer is diagnosed only in 15% of cases [3] [4]. Most patients at the time of the diagnosis are in advanced stages. However, the percentage of five-year survival rates at stage I is from 87 % to 93% [4].

Stage I ovarian cancer is limited to 1 (stage IA) or to 2 (stage IB) ovaries. In 2014 classification version time and conditions under which capsule rupture undergone are valuable. If there is an intraoperative spill it is IC1 stage and IC2 for cases with rupture unrelated to surgery. It is necessary to undertake the cytological examination of peritoneal washes or ascites in situations with tumor rupture [17].

It is important to note that patients suspected for stage I ovarian cancer incur intraoperative validation for borderline ovarian tumour. This converse from malignant neoplasm often occurs in young patients and lets to perform organ-preserving surgery.

Stage II

Diagnosis at this stage seems challenging. Conditions with stage II characteristics can be determined from 16% to 20% of tumors [4].

This stage can be defined as an involvement of the pelvic organs located intraperitoneal in close proximity to the ovaries and fallopian tubes but with no tumor spread beyond the pelvis. The main features that need to be relied upon in diagnosing stage II are the implication of either one or both ovaries or fallopian tubes with extensions and/or implants on the surface of the uterus and tubes or a combination of these characteristic, or the tumor spreading to other intraperitoneal organs within the pelvis. It should be noted that the tumor at this stage is amenable to adjuvant chemotherapy. Stage 1C was considered unnecessary and was removed from the updated version [17].

Stage III

Stage III includes conditions with one or two ovaries or fallopian tubes involvement, or primary peritoneal cancer, with cytologically or histologically confirmed spread to the peritoneum outside the pelvis and metastases to the retroperitoneal lymph nodes or both of these conditions [17]. The

Table №1. 2014 FIGO and TNM staging for ovarian, fallopian tube and peritoneal cancer

FIGO stage	Subcategory	Definition	TNM stage
I	Tumor confined to ovaries or fallopian tubes		
	A	Tumor one ovary (capsule intact) or fallopian tube	T1a-N0-M0
	B	Tumor both ovaries (capsules intact) or fallopian tubes	T1b-N0-M0
	C	Tumor one or both ovaries or fallopian tubes, with any of the following: C1: Surgical spill C2: Capsule ruptured before surgery or tumor on ovarian or fallopian tube surface C3: Malignant cells in the ascites or peritoneal washings	T1c1-N0-M0 T1c2-N0-M0 T1c3-N0-M0
II	Tumor involves one or both ovaries or fallopian tubes with pelvic extension (below the pelvic brim) or primary peritoneal cancer		
	A	Extension and/or implants on uterus and/or fallopian tubes and/or ovaries	T2a-N0-M0
	B	Extension to other pelvic intraperitoneal tissues	T2b-N0-M0
III	Tumor involves one or both ovaries or fallopian tubes or primary peritoneal cancer with cytologically or histologically confirmed spread to the peritoneum outside the pelvis and/or metastasis to the retroperitoneal lymph nodes		
	A	A1: Positive retroperitoneal lymph nodes only (cytologically or histologically proven): A1(i) Metastasis ≤ 10 mm A1(ii) Metastasis > 10 mm A2: Microscopic extrapelvic (above the pelvic brim) peritoneal involvement with or without positive retroperitoneal lymph nodes	T3a2-N0/N1-M0
	B	Macroscopic peritoneal metastasis beyond the pelvis ≤ 2 cm in greatest dimension, with or without metastasis to the retroperitoneal lymph nodes	T3b-N0/N1-M0
	C	Macroscopic peritoneal metastasis beyond the pelvis > 2 cm in greatest dimension, with or without metastasis to the retroperitoneal lymph nodes (includes extension of tumor to capsule of liver and spleen without parenchymal involvement of either organ)	T3c-N0/N1-M0
IV	Distant metastasis excluding peritoneal metastasis		
	A	Pleural effusion with positive cytology	Any T, any N, M1
	B	Parenchymal metastases and metastases to extra-abdominal organs (including inguinal lymph nodes and lymph nodes outside of the abdominal cavity)	Any T, any N, M1

most cases of ovarian cancers is detected at this stage (84% of stage III is IIIC) and for histological grade is high-grade serous carcinoma [22]. According to the results of the studies, it should also be noted the main factor influencing the disease-free survival is the fact that there is metastatic lymph nodes where the number metastases has no predictive value [23] [24].

The most significant change due to 2014 revision lies in formation a subdivision in stage III. A new stage IIIA1 includes all cases of exclusively retroperitoneal lymph nodes involvement. The occurrence frequency of such cases is less than 10 % of ovarian carcinomas [6]. Stage IIIA1 undergoes further ramification depending on the size of metastatic lesion in lymph node. It is important to take the measurements of the metastatic mass within lymph node and not the overall lymph node size. Moreover, pathological state of lymph nodes must be histologically or cytologically verified. If the size of the metastasis in the largest dimension is 10 mm or less, then stage IIIA1i is assigned. If the metastasis is more than 10 mm in its largest dimension, then thus is stage IIIA1ii. Some studies maintain that patients with stage IIIA1 have the best prognosis compared with patients with involvement of abdominal peritoneum [25] [26] [27].

The extension of peritoneal involvement affects the patient's prognosis. Microscopic focuses of disease regard to stage IIIA2. All perceptible to the eye metastases refer to stage IIIB and stage IIIC according to its measurements. If the size of macroscopic metastasis is 2 cm or less it is classified as stage IIIB, and metastases larger than 2 cm as stage IIIC.

The spread of pathological process on the capsule of the liver or spleen serves as a criterion for stage IIIC. However, such disease sites should be distinguished from isolated parenchymal metastases, which are already refer to stage IVB.

Stage IV

Stage IV disease is defined as a stage of distant metastases. It includes pleural effusion with positive cytology or biopsy (Stage IVA), parenchymal metastases and metastases to extra-abdominal sites.

It is of importance to note that inguinal lymph nodes now relate to distant group of nodes. Thus, metastases to inguinal lymph nodes, supraclavicular lymph nodes (Sister Mary Joseph nodes), umbilical metastases and transmural lesions of the intestinal wall involving the mucous membrane are considered as stage IVB [17] [28].

Resectability assessment.

As it was mentioned before from 58.5% [1] to 62% [4] of patients reveal advanced stages with peritoneal involvement. So it is pivotal to analyze the extent of peritoneal dissemination. It is generally scored according to the Peritoneal Cancer In-

dex (PCI), described by Jacquet and Sugarbaker [29]. PCI consolidates the distribution of peritoneal implants at 13 abdominal and pelvic regions with their size. Surgery is a gold standard of peritoneal cancer (PC) evaluation but it is rarely performed at the moment giving place to imaging modalities: CT (used more frequent), MRI and PET/CT. Precise preoperative assessment of PCI is important for distinction the patient for those who will benefit from primary debulking surgery and can reach optimal cytoreduction and those who are unsuitable for operation and are candidates for neoadjuvant chemotherapy in order to shrink the tumor mass before secondary debulking [30]. Moreover, a multidisciplinary approach is important. As the above criteria are tentative, frequently the same PCI can lead to different treatment tactics in different medical centers. Thus, the capabilities of a particular surgeon take centre stage in patient management and choice of treatment tactic.

Another predictive model was developed by Suidan et al. (2014) based on the results of prospective designed, non-randomized two centres study involving 669 patients. According to it the suboptimal rate was directly proportional to the predictive value score. There are 3 clinical and 6 radiologic criteria significantly associated with suboptimal debulking [31]:

- age ≥ 60 years
- CA-125 ≥ 500 U/mL
- ASA 3-4 (the six-category physical status classification system)
- Lesions > 1 cm in the small bowel mesentery
- Root of the superior mesenteric artery
- Diffuse small bowel adhesions/thickening
- Lesser sac
- Suprarenal retroperitoneal lymph nodes > 1 cm
- Splenic hilum/ligament > 1 cm

Having regard to the fact that surgical staging remains the gold standard, imaging techniques can reduce the number of diagnostic laparoscopy and minimize surgical risk and accurately establish the tumor expansion.

Ultrasound.

Ultrasound is used for primary evaluation of indeterminate adnexal masses. According to the ESUR Female Imaging Sub-Committee guidelines it is the first imaging modality in management of suspected ovarian cancer after clinical assessment and CA-125 analysis [32]. The main advantages of US are absence of radiation exposure, low cost, wide availability and high sensitivity. In ascites informational value of US in assessing the local tumor spread increases. [15] [33]

Technical complexity for staging by US should be noted. The main limitations are poor visibility of mesenteric serosal surfaces [15], ovaries dislocation in women with a history of child

Table №2. Prediction of surgical cytoreduction by CT scan

Author (Ref.)	n	Sensitivity	Specificity	PPV	NPV
Nelson et al. (1993) [39]	34	92 %	79 %	67 %	96 %
Meyer et al. (1995) [40]	28	58 %	100 %	100 %	76 %
Bristow et al. (2000) [41]	41	100 %	85 %	88 %	100 %
Dowdy et al. (2004) [42]	87	52 %	90 %	68 %	82 %
Qayyum et al. (2005) [43]	137 (CT + MRI)	76 %	99 %	94 %	96 %
Axtell et al. (2007) [44]	65	79 %	75 %	-	-
Jung et al. (2010) [45]	77	-	80 %	77 %	-
Fujwara Et al. (2011)[46]					
Model 1	98	50 %	97 %	50 %	97 %
Model 2	98	58 %	99 %	50 %	99 %
Borley et al. (2014) [47]	70	69 %	71 %	75 %	65 %
Kim et al. (2014) [48]	118	-	100 %	100 %	-
Son et al. (2016) [49]	327	71 %	73 %	69 %	92 %

birth. Moreover, it is hardly possible to visualize lesion's wall upper than 7 cm with transvaginal access. Presence of excess fat masses in the abdomen and peritoneal adhesions reduce the possibilities of transabdominal US. The operator dependency of US is the disadvantage.

Computed Tomography.

CT is the standard technique in evaluating the extent of disease in patient with suspected ovarian cancer and in assessing the feasibility of surgical optimal resection. Based on European Society of Urogenital Radiology, American College of Radiology, European Society for Medical Oncology, The American Society of Clinical Oncology and the Society of Gynecologic Oncology, National Comprehensive Cancer Network and British Gynaecological Cancer Society data, information obtained by CT scan allows to stratify the patients into two main groups: those who will benefit from primary debulking surgery with following adjuvant chemotherapy and those who is more suitable for neoadjuvant chemotherapy with interval cytoreductive surgery [32] [34] [35] [36] [37] [38]. The results of the main studies: sensitivity, specificity, positive predictive value and negative predictive value are given in Table 2.

CT is also useful for image-guided biopsy of ovarian mass and omentum for establishing the

diagnosis [15], for detecting the recurrence of the disease and for monitoring treatment response [50]. Due to short examination time CT does not deliver malaise in patients with ascites. CT is fare well at involvement assessment of the pelvic ureter and uterine serosa, the presence of neoplastic lesions at the peritoneum, omentum, mesentery, liver, spleen, lymph nodes and lung parenchyma [34].

Regarding the technical protocol image acquisition should be performed during the portal venous phase (at 70–90 seconds after the injection of contrast material) with section thickness of 3–5 mm at an interval of 3–4 mm in the axial, coronal and sagittal planes [32] (Fig. 1, fig. 2).

The major CT limitation is its restriction in detecting small (<5 mm) bowel surface, mesenteric focuses and peritoneal metastases with the absence of ascites [34]. Contraindication to contrast agents, ionising radiation exposure, pregnancy and operator dependence are other limitations. CT is not for extensive use in differentiating benign from malignant lesions due to its lower soft tissue contrast [33].

Magnetic Resonance Imaging.

MR imaging is the gold standard of differential diagnosis in undetermined adnexal masses [32][37]. For staging this technique do not form

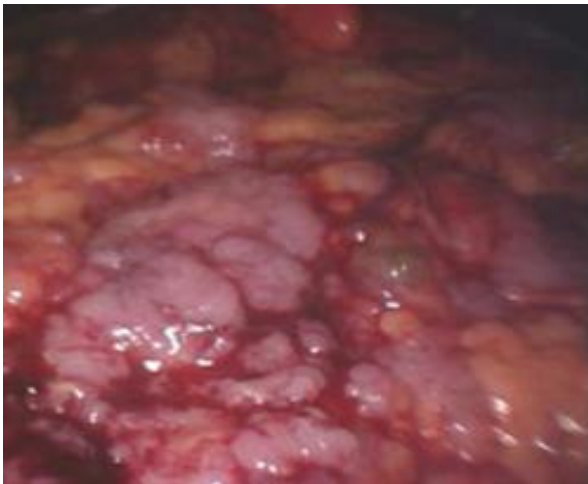


Fig. 1 а (Рис. 1 а)

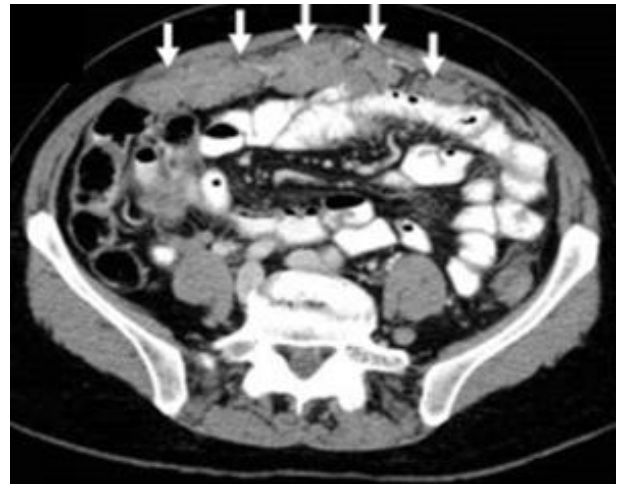

Fig. 1 б (Рис. 1 б)

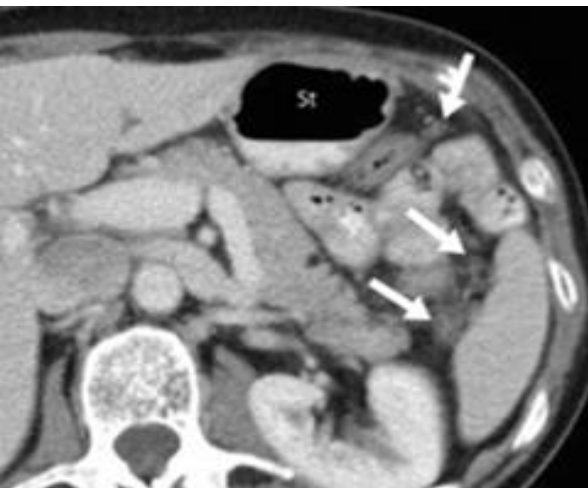


Fig. 1 с (Рис. 1 в)

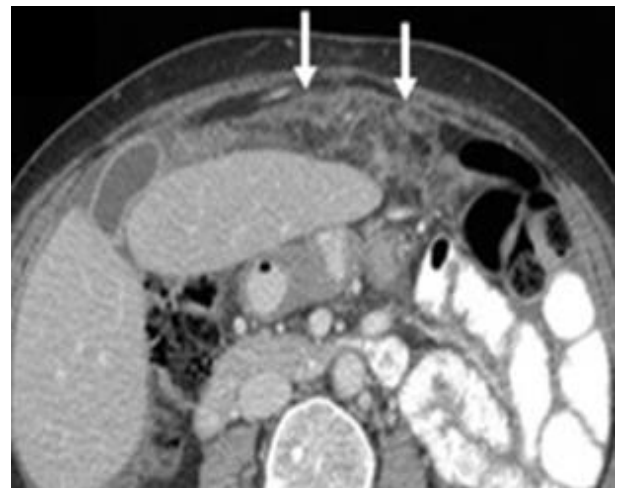

Fig. 1 d (Рис. 1 г)

Fig. 1. MSCT, ovarian cancer. Peritoneal disease of the greater omentum.

(a) A laparoscopic view. (b) A transverse MSCT slice after oral and i.v. contrast administration. The greater omentum has a masslike appearance (arrows). (c) Disseminated soft tissue deposits in the omentum (arrows). St - stomach. (d) Peritoneal dissemination the greater omentum may sometimes only appear as a hazy stranding (arrows) [98].

Рис. 1. МСКТ, рак яичников. Метастатическое поражение большого сальника.

(а) Картина при лапароскопии. (б) Поперечный срез МСКТ с пероральным и внутривенным контрастированием. Большой сальник имеет вид единого конгломерата (стрелки). (в) Дис-семированные мягкотканые имплантационные метастазы в большом сальнике (стрелки). St - желудок. (г) Перитонеальная диссеминация с вовлечением большого сальника в виде незначительной его тяжистости (стрелки) [98].

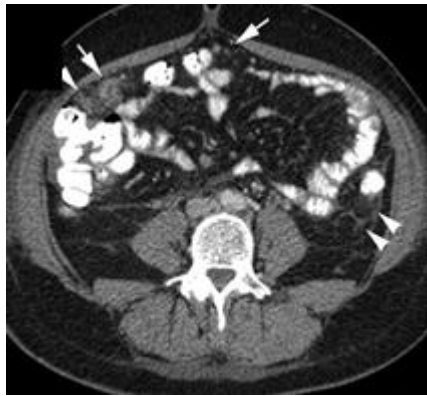

Fig. 2 а (Рис. 2 а)

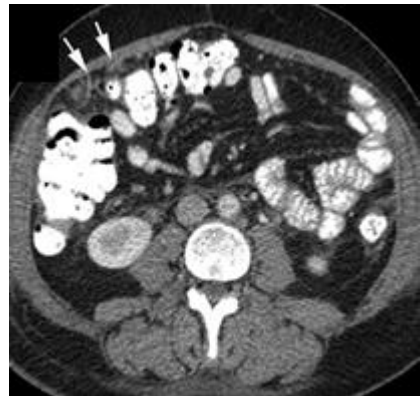

Fig. 2 б (Рис. 2 б)

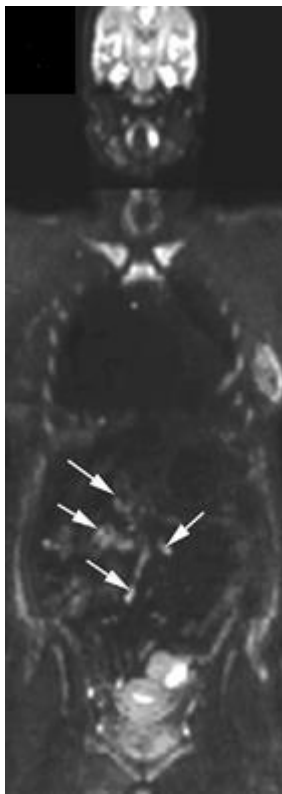


Fig. 2 в (Рис. 2 в)

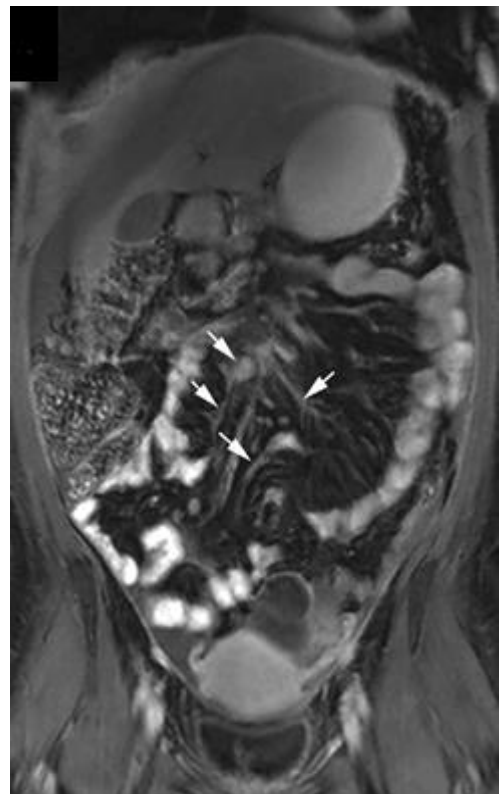


Fig. 2 д (Рис. 2 г)

Fig. 2. WB-DWI MRI, and MSCT, ovarian cancer.

Axial (a, b) Axial CT-scans shows omental deposits (arrows) and deposits in the left laterocolic peritoneum and paracolic space (arrowheads). WB-DWI MRI (b1000) shows hyperintense confluent deposits (arrows) at the (c) coronal (b1000) DWI-sequence, involving multiple major jejunal and ileal arterial branches of the superior mesenteric artery (arrows) at the (d) coronal contrast-enhanced T1-weighted image [99].

Рис. 2. ДВ-МРТ, и КТ, рак яичников.

Аксиальные срезы (а, б): сальниковые депозиты (стрелки) и солидные метастазы по брюшине толстой кишки в околотолстокишечном пространстве (наконечники стрел); На (в) корональных ДВИ всего тела с b-фактором 1000 отмечаются гиперинтенсивные сливающиеся очаги (стрелки), вовлечение тощекишечной и подвздошной артериальных ветвей верхней брыжеечной артерии (стрелки) на (г) посткорональных T1-ВИ с контрастным усилением [99].

part of routine investigations. It is a second-line modality in advanced ovarian cancer assessment. MRI is an problem-solving technique for the staging of ovarian cancer when there are questionable findings on CT scans as well as in the presence of contraindications to CT procedure such as iodinated contrast agents allergy, mild-to-moderate renal insufficiency and pregnancy [7] [15] [32] [34] [35] [37] [38].

As for benefit MRI can provide excellent tissue differentiation (Fig.3). Correlation of apparent diffusion coefficient and histologic grade of epithelial ovarian cancer was defined in several studies [51]. Similarly, Stein et al. (2017) showed the ability of multiparametric MR imaging not just to distinguish benign and malignant neoplasms but also to differentiate subtypes of ovarian cancer [52].

In assessing the prevalence of peritoneal carcinomatosis (PC), MRI does not have a significant advantage over CT. Certain benefits can be noted only in a limited number of areas affected by tumor lesions in PC. This is identification of right diaphragmatic disease according to Fehniger et al. (2016) [53]. Employment of MRI with diffusion-weighted imaging and delayed contrast enhancement in preoperating evaluation was displayed in Low et al. study (2014). According to their data, the peritoneal cancer index (PCI) in 35 patients (5 with ovarian cancer) received by MRI with DWI and DCE was more accurate compared with CT [54].

Data on MRI in assessing the feasibility of achieving optimal cytoreduction has lack of information. The main studies are listed in the table 3.

Recently, Kasper et al. (2017) published a study where systematic scoring system based on operative and MRI findings was elaborated. According to author, this Kasper system can be used for predicting non-optimal cytoreduction [59]. Prospective analysis of whole body MRI using DWI in 32 patients showed better results for assessment of bowel serosal lesions and mesenteric implants than CT and FDG-PET/CT. Metastatic spread to thoracic cavity could be rated at the same level as at PET/CT [60].

Main technical specifications are section thickness for axial acquisitions less than 5 mm, contrast-enhanced acquisitions no more than 5 minutes after intravenous contrast administration due to contrast diffusion into ascites and following hyperintense signal in intraperitoneal fluid, obscuring peritoneal lesions.

There are several restrictions for MRI. First of all, the basic are claustrophobia, metal components, cochlear implants, cardiac pacemaker incompatible with MRI [33]. Important limitations are long examination time, vena cava inferior syndrome occurred in patients in a horizontal position, technical difficulties in covering a large field

of view with high resolution and difficulties in reproducibility and analyzing the results [30]. After the thirty-minute study obtained information inevitably contains artifacts from the common patient's movement or intestinal motility during the examination [34]. But it is important to note that applying functional MRI techniques using diffusion-weighted MR imaging, dynamic contrast enhanced MR imaging we can overcome limitations of CT staging [28]. Moreover, functional MR imaging is able to minimize artifacts derived from the respiration and movements of the patient by reducing the time of study. The expensiveness of the procedure is the main disadvantage.

PET/CT

Despite its additional value in comparison to conventional imaging, PET/CT is not a routine method for initial examination of advanced ovarian cancer, is not recommended for routine preoperative staging and is, similarly to MRI, a problem-solving notability [34] [35] [37] [38] [61].

For initial diagnosis PET/CT shows good results in differentiation benign disease from malignant. However, PET/CT does not distinguish borderline and malignant tumors with high accuracy [62].

The main administration of PET/CT for staging ovarian cancer is lymph nodes assessment. PET/CT may overcome some major limitations of conventional imaging and reveal sites of disease which are not visible on conventional techniques. This is a case of metastatic lymph nodes smaller than 1 cm. An inflammatory lymph node larger than 1 cm can often be mistaken for metastatic [62]. Poor accuracy in detecting metastatic lymph nodes by CT and MRI should be noted. PET/CT has greater accuracy in assessing lymph nodes predominantly in focuses outside the abdominal cavity [63] [64]. Kitajima et al. (2008) reported 89% sensitivity and 94% accuracy for FDG-PET/CT in detecting metastatic lymph nodes and 37% sensitivity and 87% accuracy for CT [65]. This results confirm other investigators, reporting better accuracy and sensitivity for PET/CT over CT and MRI (73% and 96% for PET/CT versus 42% and 95%, respectively, for CT and 54% and 88%, respectively, for MRI) [66] and 75.5% sensitivity and 98.1% accuracy, respectively [67]. Moreover, Bharwani et al. (2011) demonstrated better mediastinum and supraclavicular region PET/CT assessment over conventional techniques [68]. The same results have other authors evaluating supradiaphragmatic metastatic extension in their studies [63] [64] [69] [70].

PET/CT contribution in examination of peritoneal spread needs further researches. Based on present knowledge PET/CT is not superior to the CT and MRI in evaluating intra-abdominal disease [64] [71]. Certain advantages were shown in Hynninen et al. study (2013) where the PET/CT

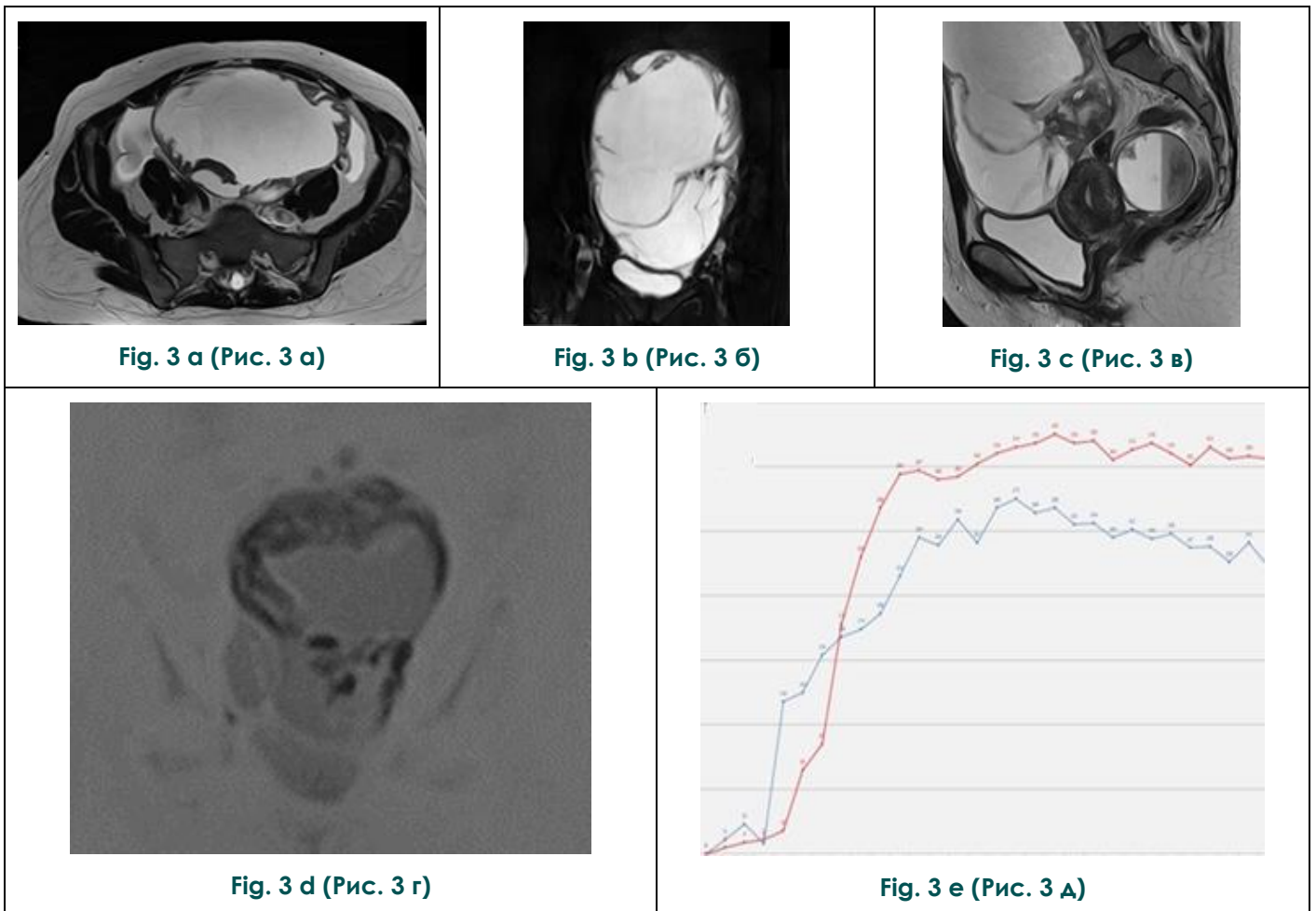


Fig. 3. MRI, in borderline cystadenoma in the left ovary.

(a) Axial T2-weighted image. (b) Coronal T2-weighted image in FatSat mode. (c) Sagittal T2-weighted image. (d) Coronal DWI, inversion. (e) Contrast accumulation curve: the blue - myometrium; red - solid component of the tumor (own observation).

Рис. 3. МРТ, при пограничной цистаденоме левого яичника.

(а) Аксиальное Т2-взвешенное изображение. (б) Корональное Т2-взвешенное изображение в режиме FatSat. (в) Сагитальное Т2-взвешенное изображение. (г) Корональное ДВИ, инверсионное. (д) График накопления контрастного препарата: голубой - в миометрии; красный - в солидном компоненте опухоли (собственное наблюдение).

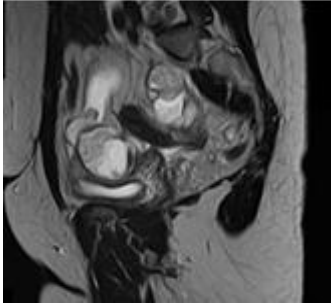


Fig. 4 a (Рис. 4 а)

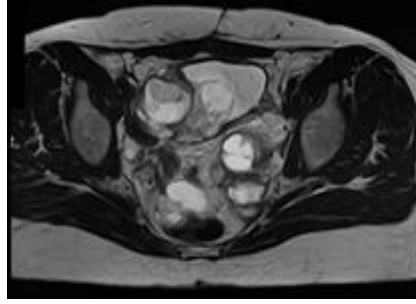


Fig. 4 b (Рис. 4 б)

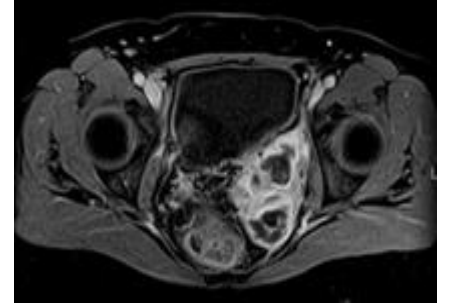


Fig. 4 c (Рис. 4 в)

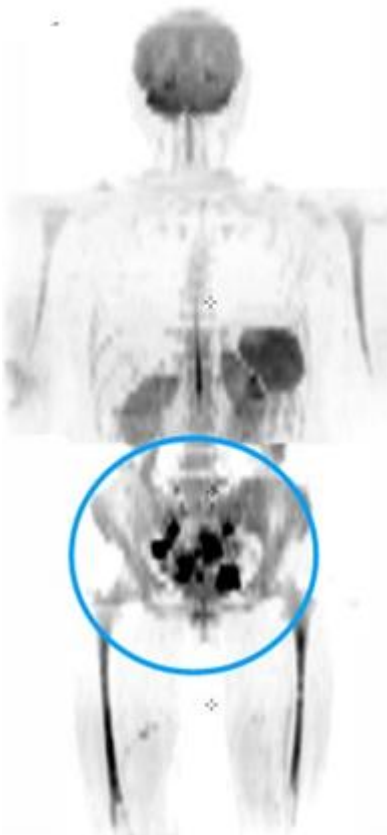


Fig. 4 d (Рис. 4 г)

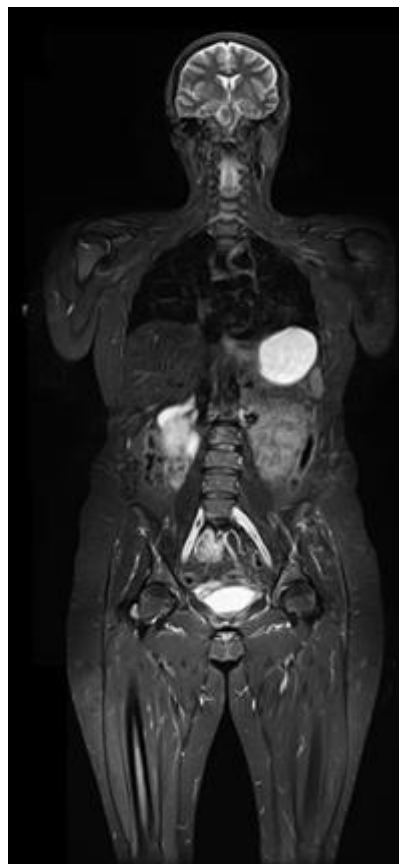


Fig. 4 e (Рис. 4 д)

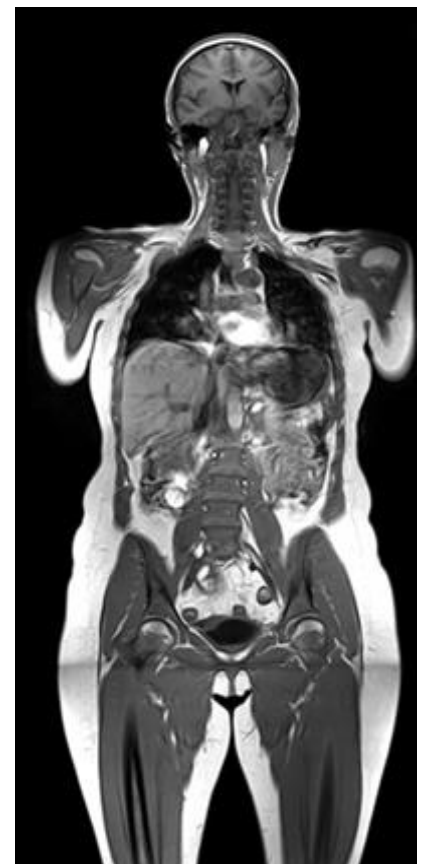

Fig. 4 f (Рис. 4 е)

Fig. 4. MRI, and WB-DWI/MRI, in ovarian cancer.

(a) Sagittal T2-weighted image. (b) Axial T2-weighted image. (c) Axial T1-weighted image in FatSat mode. (d) Whole body DWI, inversion. (e) Whole body T2-weighted image in FatSat mode. (f) Whole body T1-weighted image.

Рис. 4. МРТ, и ДВ-МРТ, при раке яичника.

(а) Сагиттальное Т2-взвешенное изображение. (б) Аксиальное Т2-взвешенное изображение. (в) Аксиальное Т1-взвешенное изображение в режиме FatSat. (г) Диффузионно-взвешенное изображение всего тела, инверсионное. (д) Диффузионно-взвешенное изображение всего тела в режиме FatSat. (е) Т1-взвешенное изображение всего тела.

Table №3. Prediction of surgical cytoreduction by MRI

Author (Ref.)	n	Sensitivity	Specificity	PPV	NPV
Forstner et al. (1995)[55]	50	91 %	-	91 %	97 %
Low et al. (2012)[56]	5	75 %	-	-	-
Espada et al. (2013)[57]	34	37.5% - 87.5%	76.9% - 94.6%	50% - 60%	74.2% - 95.2%
Solopova et al. (2017)[58] (Fig. 4)	73	78,3 %	78 %	-	-

role in the diagnosis of peritoneal carcinomatosis was assessed: satisfactory results have been received for tumoral implants in 2 sites: diaphragm and bowel mesentery. Lesions larger than 5 mm along subdiaphragmatic peritoneal surfaces were detected by PET/CT with sensitivity 74% and accuracy 78%. For CT only sensitivity and accuracy were 47% and 55%. In the bowel mesentery PET/CT was also proven to have a better CT only (sensitivity 56% for PET/CT and 19% for CT, accuracy 66% for PET/CT and 41% for CT) [64]. Keeping in mind all the information obtained by PET/CT it can be possible to better identify patients with low probability of performing optimal cytoreduction. It is reasonable to direct such women for secondary debulking surgery after neoadjuvant chemotherapy [35] [62].

PET/CT major limitations are common to CT alone: contraindication for iodine-based contrast agent, in particular renal insufficiency, hyperthyroidism, iodine allergy. It should be noted the high cost of the study, the presence of the PET/CT equipment only in specialized centers and high dependence in the interpretation of the findings on the operator. The sensitivity is limited to foci less than 5 mm, which leads to false-negative results when assessing tumor burden with diffuse peritoneal spread [65]. Also false-negative results can be caused by small amount of malignant cells. In such conditions a glucose uptake is not evident in PET images [72]. On the other hand, the non-optimal specificity of the method leads to false-positive results. These cases require careful evaluation as they can be determined by increased accumulation and uptake of FDG due to inflammation.

PET/MRI

This is a new technique that can be useful in the evaluation of tumors of different localization. Since application possibility PET/MRI is limited to a few specialized centers, future exploration in multi-center randomized clinical trials should be performed to reveal the part of the PET/MRI in the diagnosis of advanced ovarian cancer.

Up to date several studies were performed allowing to conclude PET/MRI can overcome the limitations of PET/CT and to primary delineate tumor better due to its morphologic high soft tissue contrast [73] (Fig. 5).

Among the other advantages of PET/MRI should be attributed its lower ionizing radiation dose compared to PET/CT [74]. The main restrictions of this method are low availability to the population and high cost of the procedure.

Treatment control.

The «gold standard» treatment of stage II, III, IV ovarian cancer are comprehensive surgical staging and primary cytoreductive surgery with following adjuvant chemotherapy [32] [35] [37] [38]. The main purpose of operation is to leave in the abdominal cavity no tumor tissue. It is pivotal because the size of the residual disease is the major determinant for patient’s prognosis [75]. To the date it is estimated the necessity to achieve complete cytoreduction with residual disease 0 cm because it has the best survival outcomes. There was established advantage of macroscopic tumor foci’s absence over primary debulking surgery to residual disease of 1–10 mm (optimal cytoreduction) in progression-free survivals and overall survival [76] [77] [78]. Primary debulking surgery to residual disease of 1–10 mm is associated with survival benefit compared to residual disease more than 10 mm [79].

At the same time there is an ongoing debate about the best management for advanced ovarian cancer. Over the last years there is an increasing number of publications demonstrating that neoadjuvant chemotherapy (NACT) followed by interval cytoreductive surgery is no worse than primary cytoreductive surgery followed by adjuvant chemotherapy in women with advanced stage ovarian cancer for survival rates [80] [81] [82] [83] [84] [85]. In the two phase III largest trials conclude - European Organization for Research and Treatment of Cancer (EORTC) trial and the CHemotherapy OR Upfront Surgery (CHORUS) trial - the median overall survival of patients was equivalent compared to the median overall survival in treatment group who undergo primary debulking sur-

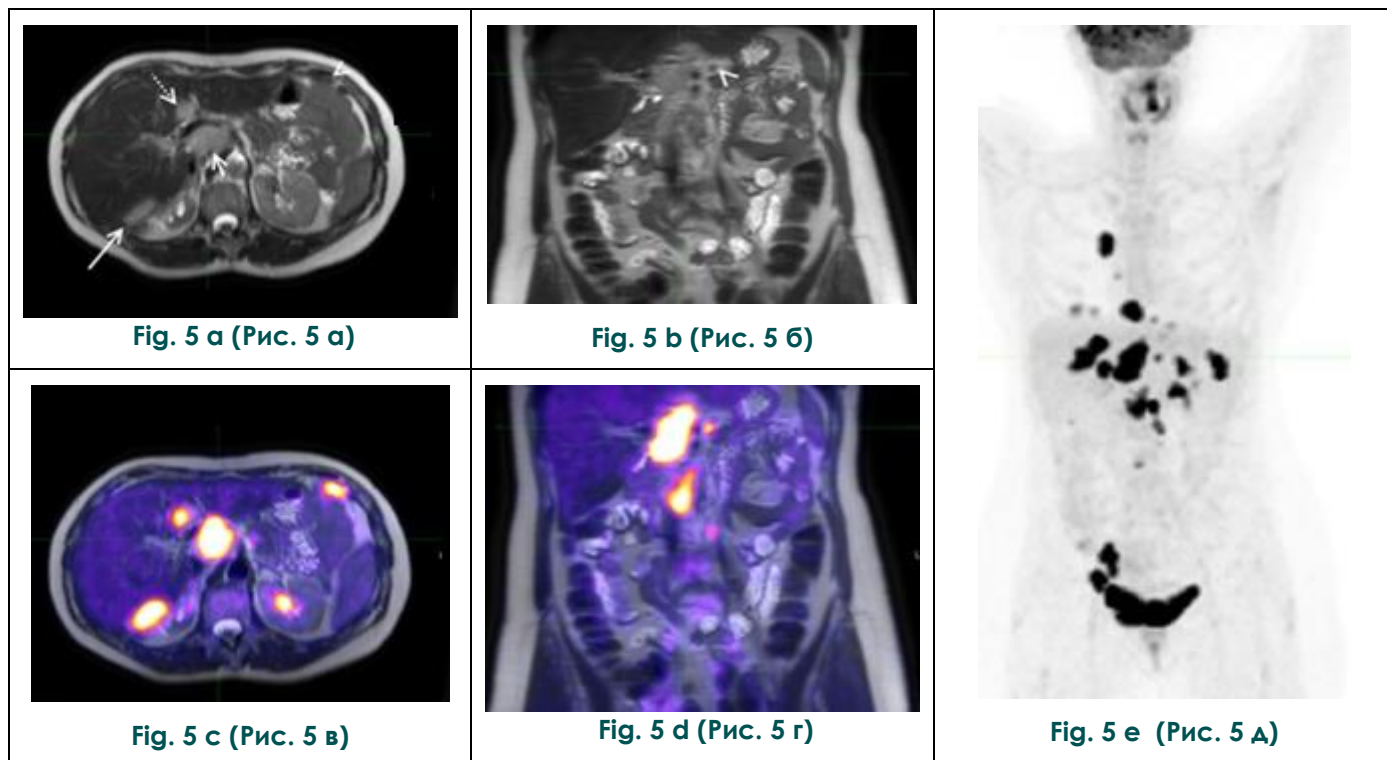


Fig. 5. PET/MRI, in ovarian cancer.

Axial and coronal T2-weighted images (a, b) show a round lesion with smooth, clear contours in segment IV of the liver (dotted arrow), intermediate to high signal foci in the liver (long arrow), the porta hepatis (short arrow) and the peritoneum (arrowheads). On PET/MRI images (c, d) malignancy of these lesions are proved by high FDG uptake. Multiple lesions at maximum intensity projection (MIP) of the whole body (e) [74].

Рис. 5. ПЭТ/МРТ, при раке яичников.

На аксиальных и корональных T2-взвешенных изображениях (а, б) визуализируется круглый очаг с ровными четкими контурами в IV сегменте печени (пунктирная стрелка), очаги, имеющие сигнал от умеренного до сильного, в печени (длинная стрелка), в воротах печени (короткая стрелка) и по брюшине (наконечники стрелок). На ПЭТ/МР томограммах (в, г) очаги повышенного захвата фтордезоксиглюкозы (злокачественные). Множественные очаги на проекции максимальной интенсивности всего тела (д) [74].

gery with following adjuvant chemotherapy [84] [85]. This allowed authors to conclude that neoadjuvant chemotherapy is an admissible alternative for patients with stage III - IV ovarian cancer, when optimal cytoreduction is not attainable.

Another conformable study is currently proceeding. TRUST, Trial on Radical Upfront Surgery in advanced ovarian cancer, is open randomized prospective multi-centre trial of the international collaboration. Its aim is to estimate what treatment mode is beneficial and to define the optimal timing of radical surgery in advanced ovarian cancer [86].

To the present day the attitude of clinical societies is in the following condition. In the ESMO guidelines released to the public in 2013 have recommended neoadjuvant chemotherapy and interval surgery for women in whom it is impossible to carry out optimal cytoreduction at initial presentation due to extensive tumour dissemination [35]. The same conclusion Society of Gynecologic Oncology and American Society of Clinical

Oncology has. The SGO and ASCO clinical practice guidelines characterize neoadjuvant chemotherapy with interval cytoreductive surgery as alternative option to primary debulking surgery in patients with high perioperative risk or low likelihood of achieving cytoreduction to <1 cm [36]. Similarly, BGCS guidelines declare that neoadjuvant chemotherapy followed by interval debulking surgery can be considered for patients with stage II - IV disease as non-inferior to primary upfront cytoreductive surgery in patients considered to be not optimally resectable because of significant disease burden [38]. According to the most recently published National Comprehensive Cancer Network guidelines 2018, for the patient with poor surgical prognosis and with bulky stage III and IV disease and who cannot undergo complete cytoreduction to residual disease 0 neoadjuvant chemotherapy followed by interval debulking surgery is preferable over the primary cytoreductive surgery [37].

Treatment Response Monitoring.

Assessment of response to chemotherapy counts on CA-125 measurement (the gold standard), clinical symptoms and visualization data [87]. It is reasonable to measure the tumor volume after 3 cycles of chemotherapy when its reduction [88], extent of enhancing walls, septations and mural nodular projections occurred [89]. Visualization data are evaluated according to the RECIST 1.1 criteria. These measurements are based on CT or MRI as second choice. But it often poses a challenge because RECIST 1.1 guidelines do not consider ascites or pleural effusion [90], cystic masses, foci <1 cm as a target, which complicate the assessment of the omental caking and serosal deposits [91]. Nevertheless, early distinction responders from non-responders to therapy can be reached not only on the tumor size criterion but also on molecular and microstructural changes by multiparametric MRI and PET/CT. Cell damage, provoked by chemotherapy, can be evaluated using DCE-MR and DW-MR imaging. Kyriazi and colleagues (2011) proved ADC to be treatment response biomarker in patients with advanced ovarian cancer. Apparent diffusion coefficients increasing after the first and the third cycles of treatment was associated with the final chemotherapy response [92]. Sala et al. (2012) received similar results. They indicated correlation between ADC with the cytotoxic effects of therapy [93]. The authors concluded DW-MR imaging to be the most appropriate imaging modality for monitoring response to neoadjuvant chemotherapy in patients with AOC. Another response biomarkers in gynecological malignancies assessed by multiparametric MRI need further exploration.

Imaging in recurrent disease.

The tumor considered to be recurrent in those cases when it is detected after a full response to the first course of chemotherapy. Interval without the tumor should be more than 6 months.

A high CA-125 serum level is suspected for presence of disease recurrence [62]. To date, the researchers have not come to a certain conclusion in choosing the best method of visualization of the site and extent of disease relapse [69]: CA-125 measurement with CT, MRI, and PET/CT are using for recurrence detection.

In cases with negative CT and MRI results PET/CT can be helpful. Two meta-analyses conducted by Gu and colleagues (2009) [94] (34 studies) and most recent by Suppiah and colleagues (2017)[95] (13 studies) proved PET/CT to be a useful supplement to current surveillance techniques. As for ovarian cancer staging PET/CT shows the best results in evaluation small peritoneal lesions and metastatic lymph nodes. Yuan et al. (2012) [66] analyzed 118 studies with 882 patients and compared PET/CT, CT and MR imaging results in detecting lymph nodes in recurrent

ovarian cancer. The sensitivity and specificity values of 73.2% and 96.7% for PET/CT, respectively, over 42.6% and 95%, respectively, for CT, and 54.7% and 88.3%, respectively, for MRI. This results lead Yuan and colleagues to the conclusion that PET/CT is a more accurate visualization method for this purpose.

Particular attention should be paid to the use of functional MR imaging in the diagnosis of relapse. Michielsen et al. (2016) evaluated the clinical expediency of using DWI in the diagnosis and prognosis of tumor resection results in patients with suspected ovarian cancer recurrence [96]. The accuracy of DWI-MRI in the detection of relapse was 94%, while the accuracy of CT was 78%. The authors concluded that the use of DWI-MRI allows to optimize treatment strategy of relapse and increases the survival of this patient group.

Another study conducted in Russia confirms the feasibility of using DWI-MRI in the pelvic relapse diagnosis. When using functional techniques in combination with standard MRI protocol, Rubtsova et al. (2017) [97] attained accuracy, sensitivity, specificity of 89%, 88% and 100% respectively. The obtained outcome allows to include DWI-MRI in examination plan for patients with unfavorable prognostic factors after chemotherapy for primary disease with the presence of biochemical relapse.

Summary.

Imaging is pivotal in the management of patients with ovarian cancer. According to ESUR, ACR, ESMO, ASCO and SGO, NCCN and BGCS imaging modality of choice for characterization of adnexal masses suspected for malignancy is US. The main methodology for assessing the extend of the tumor is CT, which is additional to surgical staging. Problem-solving modalities in staging of advanced ovarian cancer are MRI and PET/CT. MRI is a gold standard of differential diagnosis. Imaging allows to plan upcoming surgery making it more "targeted". Moreover, imaging enables to predict the possibility of performing optimal or complete cytoreduction reaching residual disease 0 cm or residual disease 1 cm after primary debulking surgery. Currently, there is a tendency to remove all macroscopic foci from the abdomen to achieve residual disease 0 cm. Women with non-resectable disease do not benefit from primary surgery and should be offered to undergo neoadjuvant chemotherapy followed by interval debulking surgery. Multi-parametric MR imaging provides molecular and metabolic information which can early distinguish responders from non-responders to chemotherapy by increasing ADC after the treatment. Relapse diagnosis is based on increased serum CA 125 level with radiological evaluation. In conditions with no biochemical recurrence imaging plays the key role in diagnosis.

DWI-MRI has high accuracy, sensitivity, specificity for relapse ovarian cancer detection.

Authors declare the absence of potential conflict of interests.

Authors transmit editorial right to article

References:

1. Kaprin A.D., Starinskii V.V., Petrova, G.V. (ed.). *Sostoyanie onkologicheskoi pomoshchi nase-leniyu Rossii v 2017 godu*. M.: MNIOI im. P.A. Gertsena, 2018 (in Russian).
2. Kaprin A.D., Starinskii V.V., Petrova G.V. (ed.). *Zlo-kachestvennyye novoobrazovaniya v Rossii v 2016 godu*. M.: MNIOI im. P.A. Gertsena, 2018 (in Russian).
3. National Institutes of Health, National Cancer Institute, Surveillance, Epidemiology, and End Results Program. 2016. Available at: <http://www.seer.cancer.gov>. See Appendix I, Surveillance, Epidemiology, and End Results Program (SEER).
4. Siegel R.L., Miller K.D., Jemal A. Cancer statistics, 2018. *CA Cancer J Clin*. 2018; 68(1): 7–30. doi: 10.3322/caac.21442
5. Meinhold-Heerlein I, Fotopoulou C., Harter P., Kurzeder C., Mustea A., Wimberger P. Et al. The new WHO classification of ovarian, fallopian tube, and primary peritoneal cancer and its clinical implications. *Archives of Gynecology and Obstetrics*. 2016; 293(4): 695–700. doi:10.1007/s00404-016-4035-8
6. Prat J. Staging Classification for Cancer of the Ovary, Fallopian Tube, and Peritoneum. *Obstetrics & Gynecology*. 2015; 126(1): 171–174. doi:10.1097/aog.0000000000000917
7. Javadi S., Ganeshan D. M., Qayyum A., Iyer R. B., Bhosale P. Ovarian Cancer, the Revised FIGO Staging System, and the Role of Imaging. *American Journal of Roentgenology*. 2016; 206(6): 1351–1360. doi:10.2214/ajr.15.15199
8. Shaw P. A., Rouzbahman M., Pizer E. S., Pintilie M., Begley H. Candidate serous cancer precursors in fallopian tube epithelium of BRCA1/2 mutation carriers. *Modern Pathology*. 2009; 22(9): 1133–1138. doi:10.1038/modpathol.2009.89
9. McCluggage W. G. Morphological subtypes of ovarian carcinoma: a review with emphasis on new developments and pathogenesis. *Pathology*. 2011; 43(5): 420–432. doi:10.1097/pat.0b013e328348a6e7
10. Sciscione A. Ovarian Cancer. In: Ferri F, editor. *Ferri's Clinical Advisor*. Philadelphia: Elsevier. 2018; 932-933. e1
11. Kurman R, Carcangiu M, Herrington C. et al. WHO Classification of tumours of female re-productive organs. Lyon: IARC Press; 2014.
12. Havrilesky L, Sanders G, Kulasingam S, et al. Development of an ovarian cancer screening decision model that incorporates disease heterogeneity: implications for potential mortality reduction. *Cancer*. 2011; 117(3): 545-53. doi: 10.1002/cncr.25624
13. Meinhold-Heerlein I, Hauptmann S. The heterogeneity of ovarian cancer. *Arch Gynecol Obstet*. 2014; 289(2): 237-9. doi: 10.1007/s00404-013-3114-3.
14. Kurman R. J., Shih I. M. The Dualistic Model of Ovarian Carcinogenesis: Revisited, Re-vised, and Expanded. *The American Journal of Pathology*. 2016; 186(4): 733–747. doi:10.1016/j.ajpath.2015.11.011
15. Miccò M., Sala E., Lakhman Y., Hricak H., Vargas H. A. Role of Imaging in the Pretreatment Evaluation of Common Gynecological Cancers. *Women's Health*. 2014; 10(3): 299–321. doi:10.2217/whe.14.19
16. Pandharipande P.V., Lowry K.P., Reinhold C., Atri M., Benson C.B., Bhosale P.R. et al. ACR Appropriateness Criteria® Ovarian Cancer Screening Expert Panel on Women's Imaging. *J Am Coll Radiol*. 2017;14(11S): 490-S499. doi: 10.1016/j.jacr.2017.08.049.
17. Prat J. Staging classification for cancer of the ovary, fallopian tube, and peritoneum. *Int J Gynaecol Obstet*. 2014; 124(1): 1-5. doi: 10.1016/j.ijgo.2013.10.001
18. Mutch D. G., Prat J. 2014 FIGO staging for ovarian, fallopian tube and peritoneal cancer. *Gynecol Oncol*. 2014; 133(3): 401–404. doi:10.1016/j.ygyno.2014.04.013
19. Prat J. Ovarian carcinomas: five distinct diseases with different origins, genetic alterations, and clinicopathological features. *Virchows Archiv*. 2012; 460(3): 237–249. doi:10.1007/s00428-012-1203-5
20. Suh D. H., Kim T. H., Kim J.-W., Kim S. Y., Kim H. S., Lee T. S. et al. Improvements to the FIGO staging for ovarian cancer: reconsideration of lymphatic spread and intraoperative tumor rupture. *Journal of Gynecologic Oncology*. 2013; 24(4): 352–358. doi:10.3802/jgo.2013.24.4.352
21. Mann J.W., Chalas E., Valea F.A. Cancer of the ovary, fallopian tube, and peritoneum: staging and initial management. *www. UpToDate.com* (2015). Accessed 19 Jan 2016.
22. Heintz A.P., Odicino F., Maisonneuve P., Quinn M.A., Benedet J.L., Creasman W.T. et al. Carcinoma of the ovary: FIGO 26th Annual Report on the Results of Treatment in Gynecological Cancer. *Int J Gynaecol Obstet*. 2006; 95 Suppl: 161–192. doi: 10.1016/S0020-7292(06)60033-7
23. Ayhan A., Gultekin M., Taskiran C., Celik N. Y., Usubutun A., Kucukali T., Yuce K. Lymphatic metastasis in epithelial ovarian carcinoma with respect to clinicopathological variables. *Gynecol Oncol*. 2005; 97(2): 400–404. doi:10.1016/j.ygyno.2005.01.038
24. Ayhan A., Gultekin M., Dursun P., Dogan N. U., Aksan G., Guven S. et al. Metastatic lymph node number in epithelial ovarian carcinoma: Does it have any clinical significance? *Gynecol Oncol*. 2008; 108(2): 428–432. doi:10.1016/j.ygyno.2007.09.014
25. Baek S.J., Park J.Y., Kim D.Y. et al. Stage IIIc epithelial ovarian cancer classified solely by lymph node metastasis has a more favorable prognosis than other types of stage IIIc epithelial ovarian cancer. *J Gynecol Oncol*. 2008; 19(4): 223–228. doi:10.3802/jgo.2008.19.4.223
26. Cliby W. A., Aletti G. D., Wilson T. O., Podratz K. C. Is it justified to classify patients to Stage IIIc epithelial ovarian cancer based on nodal involvement only? *Gynecol Oncol*. 2006; 103(3): 797–801. doi:10.1016/j.ygyno.2006.08.047
27. Ferrandina G, Scambia G, Legge F, Petrillo M, Salutati V. Ovarian cancer patients with “node-positive-only” stage IIIc disease have a more favorable outcome than stage IIIA/B. *Gy-*

- necol Oncol. 2007; 107: 154–156. doi:10.1016/j.ygyno.2007.05.016
28. Forstner R., Meissnitzer M., Cunha T.M. Update on Imaging of Ovarian Cancer. *Curr Radiol Rep.* 2016; 4: 31. doi: 10.1007/s40134-016-0157-9
29. Jacquet P., Sugarbaker P. Clinical research methodologies in diagnosis and staging of patients with peritoneal carcinomatosis. *Cancer Treatment and Research.* 1996; 82: 359–374. doi: 10.1007/978-1-4613-1247-5_23
30. Roviello F., Pinto E., Corso G., Pedrazzani C., Caruso S., Filippeschi M. et al. Safety and potential benefit of hyperthermic intraperitoneal chemotherapy (HIPEC) in peritoneal carcinoma-tosis from primary or recurrent ovarian cancer. *Journal of Surgical Oncology.* 2010; 102(6): 663–670. doi:10.1002/jso.21682
31. Suidan R.S., Ramirez P.T., Sarasohn D.M., Teitcher J.B., Mironov S., Iyer R.B. et al. A multicenter prospective trial evaluating the ability of preoperative computed tomography scan and serum CA-125 to predict suboptimal cytoreduction at primary debulking surgery for advanced ovarian, fallopian tube, and peritoneal cancer. *Gynecol. Oncol.* 2014; 134: 455–461. doi:10.1016/j.ygyno.2014.03.079
32. Forstner R., Sala E., Kinkel K., Spencer J. A. ESUR guidelines: ovarian cancer staging and follow-up. *Eur Radiol.* 2010; 20(12): 2773–2780. doi:10.1007/s00330-010-1886-4
33. Fischerova D., Burgetova A. Imaging techniques for the evaluation of ovarian cancer. *Best Practice & Research Clinical Obstetrics & Gynaecology.* 2014; 28(5): 697–720. doi:10.1016/j.bpobgyn.2014.04.006
34. Mitchell D. G., Javitt M. C., Glanc P., Bennett G. L., Brown D. L., Dubinsky T. et al. ACR Appropriateness Criteria Staging and Follow-up of Ovarian Cancer. *J Am Coll Radiol.* 2013; 10(11): 822–827. doi: 10.1016/j.jacr.2013.07.017
35. Ledermann J. A., Raja F. A., Fotopoulou C., Gonzalez-Martin A., Colombo N., Sessa C. Newly diagnosed and relapsed epithelial ovarian carcinoma: ESMO Clinical Practice Guidelines for diagnosis, treatment and follow-up. *Annals of Oncology.* 2013; 24(suppl 6), vi24–vi32. doi:10.1093/annonc/mdt333
36. Wright A. A., Bohlke K., Armstrong D. K., Bookman M. A., Cliby W., Coleman A. et al. Neoadjuvant Chemotherapy for Newly Diagnosed, Advanced Ovarian Cancer: Society of Gynecologic Oncology and American Society of Clinical Oncology Clinical Practice Guideline. *Journal of Clinical Oncology.* 2016; 34(28), 3460–3473. doi:10.1200/jco.2016.68.6907
37. Armstrong D. K., Plaxe S. C., Alvarez R.D. et al. NCCN Clinical Practice Guidelines in Oncology, Ovarian Cancer, Including Fallopian Tube Cancer and Primary Peritoneal Cancer. Version 1. 2018. Available at nccn.org. (Accessed February 28, 2018).
38. Fotopoulou C., Hall M., Cruickshank D., Gabra H., Ganesan R., Hughes C. et al. British Gynaecological Cancer Society (BGCS) epithelial ovarian/fallopian tube/primary peritoneal cancer guidelines: recommendations for practice. *European Journal of Obstetrics & Gynecology and Reproductive Biology.* 2017; 213: 123–139. doi:10.1016/j.ejogrb.2017.04.016
39. Nelson B. E., Rosenfield A. T., Schwartz P. E. Preoperative abdominopelvic computed tomographic prediction of optimal cytoreduction in epithelial ovarian carcinoma. *Journal of Clinical Oncology.* 1993; 11(1): 166–172. doi:10.1200/jco.1993.11.1.166
40. Meyer J. I., Kennedy A. W., Friedman R., Ayoub A., Zepp R. C. Ovarian carcinoma: value of CT in predicting success of debulking surgery. *American Journal of Roentgenology.* 1995; 165(4): 875–878. doi:10.2214/ajr.165.4.7676985
41. Bristow R. E., Duska L. R., Lambrou N. C., Fishman E. K., O'Neill M. J., Trimble E. L. et al. A model for predicting surgical outcome in patients with advanced ovarian carcinoma using computed tomography. *Cancer.* 2000; 89(7): 1532–40. doi: 10.1002/1097-0142(20001001)89:7<1532::AID-CNCR17>3.0.CO;2-A
42. Dowdy S. C., Mullany S. A., Brandt K. R., Huppert B. J., Cliby W. A. The utility of computed tomography scans in predicting suboptimal cytoreductive surgery in women with advanced ovarian carcinoma. *Cancer.* 2004; 101(2): 346–352. doi:10.1002/cncr.20376
43. Qayyum A., Coakley F. V., Westphalen A. C., Hricak H., Okuno W. T., Powell B. Role of CT and MR imaging in predicting optimal cytoreduction of newly diagnosed primary epithelial ovarian cancer. *Gynecologic Oncology.* 2005; 96(2): 301–306. doi:10.1016/j.ygyno.2004.06.054
44. Axtell A. E., Lee M. H., Bristow R. E., Dowdy S. C., Cliby W. A., Raman S. et al. Multi-Institutional Reciprocal Validation Study of Computed Tomography Predictors of Suboptimal Primary Cytoreduction in Patients With Advanced Ovarian Cancer. *Journal of Clinical Oncology.* 2007; 25(4): 384–389. doi:10.1200/jco.2006.07.7800
45. Jung D. C., Kang S., Kim M. J., Park S. Y., Kim H. B. Multidetector CT predictors of incomplete resection in primary cytoreduction of patients with advanced ovarian cancer. *European Radiology.* 2009; 20(1): 100–107. doi:10.1007/s00330-009-1533-0
46. Fujwara K., Yoshino K., Enomoto T., Fujita M., Ueda Y., Miyatake T. et al. Usefulness of computed tomography in predicting cytoreductive surgical outcomes for ovarian cancer. *Arch Gynecol Obstet.* 2011; 284(6): 1501–7. doi: 10.1007/s00404-011-1864-3
47. Borley J., Wilhelm-Benartzi C., Yazbek J., Williamson R., Bharwani N., Stewart V. et al. Radiological predictors of cytoreductive outcomes in patients with advanced ovarian cancer. *BJOG: An International Journal of Obstetrics & Gynaecology.* 2014; 122(6): 843–849. doi:10.1111/1471-0528.12992
48. Kim H., Choi C., Lee Y., Kim T., Lee J., Bae D. et al. Surgical outcome prediction in patients with advanced ovarian cancer using computed tomography scans and intraoperative findings. *Taiwanese Journal of Obstetrics and Gynecology.* 2014; 53(3): 343–347. doi:10.1016/j.tjog.2013.10.041
49. Son H., Kim S., Kwon B., Kim M., Kim C., Cho S. Preoperative prediction of suboptimal resection in advanced ovarian cancer based on clinical and CT parameters. *Acta Radiologica.* 2016; 58(4): 498–504. doi:10.1177/0284185116658683
50. Coakley F. V., Choi P. H., Gougoutas C. A., Pothuri B., Venkatraman E., Chi D. et al. Peritoneal Metastases: Detection with Spiral CT in Patients with Ovarian Cancer. *Radiology.* 2002; 223(2): 495–499. doi:10.1148/radiol.2232011081
51. Oh J.-W., Rha S. E., Oh S. N., Park M. Y., Byun J. Y., Lee A. Diffusion-weighted MRI of epithelial ovarian cancers: Correlation of apparent diffusion coefficient values with histologic grade and surgical stage. *European Journal of Radiology.* 2015; 84(4): 590–595. doi:10.1016/j.ejrad.2015.01.005
52. Stein E. B., Wasnik A. P., Sciallis A. P., Kamaya A.,

- Maturen K. E. MR Imaging–Pathologic Correlation in Ovarian Cancer. *Magnetic Resonance Imaging Clinics of North America*. 2017; 25(3): 545–562. doi:10.1016/j.mric.2017.03.004
53. Fehniger J., Thomas S., Lengyel E., Liao C., Tenney M., Oto A., Yamada S. D. A prospective study evaluating diffusion weighted magnetic resonance imaging (DW-MRI) in the detection of peritoneal carcinomatosis in suspected gynecologic malignancies. *Gynecologic Oncology*. 2016; 142(1): 169–175. doi:10.1016/j.ygyno.2016.04.018
54. Low R. N., Barone R. M., Lucero J. Comparison of MRI and CT for Predicting the Peritoneal Cancer Index (PCI) Preoperatively in Patients Being Considered for Cytoreductive Surgical Procedures. *Annals of Surgical Oncology*. 2014; 22(5): 1708–1715. doi:10.1245/s10434-014-4041-7
55. Forstner R., Hricak H., Occhipinti K., Powell C., Frankel S., Stern J. Ovarian cancer: staging with CT and MR imaging. *Radiology*. 1995; 197(3): 619–626. doi:10.1148/radiology.197.3.7480729
56. Low R., Barone R. Combined diffusion-weighted and gadolinium-enhanced MRI can accurately predict the peritoneal cancer index preoperatively in patients being considered for cytoreductive surgical procedures. *Ann Surg Oncol*. 2012; 19: 1394–1401. doi: 10.1245/s10434-012-2236-3
57. Espada M., Garcia-Flores J., Jimenez M., Alvarez-Moreno E., De Haro M., Gonzalez-Cortijo L. et al. Diffusion-weighted magnetic resonance imaging evaluation of intra-abdominal sites of implants to predict likelihood of suboptimal cytoreductive surgery in patients with ovarian carcinoma. *Eur Radiol*. 2013; 23: 2636–2642. doi: 10.1007/s00330-013-2837-7
58. Solopova A., Ternovoy S., Alipov V., Makatsariya A. Use of integrated diffusion-weighted magnetic-resonance imaging in pre-operative evaluation of resectability advanced ovarian cancer. *Obstetrics, gynecology and reproduction*. 2017; 11 (2): 5–11 (in Russian). doi: 10.17749/2313-7347.2017.11.2.005-011
59. Kasper S. M., Dueholm M., Marinovskij E., Blaakær J. Imaging diagnostics in ovarian cancer: magnetic resonance imaging and a scoring system guiding choice of primary treatment. *European Journal of Obstetrics & Gynecology and Reproductive Biology*. 2017; 210: 83–89. doi:10.1016/j.ejogrb.2016.10.034
60. Michielsen K., Vergote I., Op de Beeck K., Amant F., Leunen K., Moerman P. et al. Whole-body MRI with diffusion-weighted sequence for staging of patients with suspected ovarian cancer: a clinical feasibility study in comparison to CT and FDG-PET/CT. *Eur Radiol*. 2014; 24(4): 889–901. doi:10.1007/s00330-013-3083-8
61. Marzola M. C., Chondrogiannis S., Rubello D. Fludeoxyglucose F 18 PET/CT Assessment of Ovarian Cancer. *PET Clinics*. 2018; 13(2): 179–202. doi:10.1016/j.cpet.2017.11.005
62. Kitajima K., Ebina Y., Sugimura K. Present and future role of FDG-PET/CT imaging in the management of gynecologic malignancies. *Jpn J Radiol*. 2014; 32(6): 313–323. doi:10.1007/s11604-014-0317-x
63. Fruscio R., Sina F., Dolci C., Signorelli M., Crivellaro C., Dell'Anna T. et al. Preoperative 18F-FDG PET/CT in the management of advanced epithelial ovarian cancer. *Gynecol Oncol*. 2013; 131(3): 689–693. doi:10.1016/j.ygyno.2013.09.024
64. Hynninen J., Kemppainen J., Lavonius M., Virtanen J., Matomäki J., Oksa S. et al. A prospective comparison of integrated FDG-PET/contrast-enhanced CT and contrast-enhanced CT for pretreatment imaging of advanced epithelial ovarian cancer. *Gynecol Oncol*. 2013; 131(2): 389–394. doi:10.1016/j.ygyno.2013.08.023
65. Kitajima K., Murakami K., Yamasaki E., Kaji Y., Fukasawa I., Inaba N. et al. Diagnostic accuracy of integrated FDG-PET/contrast-enhanced CT in staging ovarian cancer: comparison with enhanced CT. *Eur J Nucl Med Mol Imaging*. 2008; 35(10): 1912–1920. doi:10.1007/s00259-008-0890-2
66. Yuan Y., Gu Z.-X., Tao X.-F., Liu S.-Y. Computer tomography, magnetic resonance imaging, and positron emission tomography or positron emission tomography/computer tomography for detection of metastatic lymph nodes in patients with ovarian cancer: A meta-analysis. *Eur J Radiol*. 2012; 81(5): 1002–1006. doi:10.1016/j.ejrad.2011.01.112
67. Signorelli M., Guerra L., Pirovano C., Crivellaro C., Fruscio R., Buda A. et al. Detection of nodal metastases by 18F-FDG PET/CT in apparent early stage ovarian cancer: A prospective study. *Gynecol Oncol*. 2013; 131(2): 395–399. doi:10.1016/j.ygyno.2013.08.022
68. Bharwani N., Reznek R. H., Rockall A. G. Ovarian Cancer Management: The role of imaging and diagnostic challenges. *Eur J Radiol*. 2011; 78(1): 41–51. doi:10.1016/j.ejrad.2010.11.039
69. Mapelli P., Incerti E., Fallanca F., Gianolli L, Picchio M. Imaging biomarkers in ovarian cancer: the role of ¹⁸F-FDG PET/CT. *Q J Nucl Med Mol Imaging*. 2016; 60(2): 93–102
70. Schmidt S., Meuli R. A., Ahtari C., Prior J. O. Peritoneal Carcinomatosis in Primary Ovarian Cancer Staging. *Clin Nucl Med*. 2015; 40(5): 371–377. doi:10.1097/rlu.0000000000000768
71. Kumar L., Pramanik R., Kumar S., Bhatla N., Malik S. Neoadjuvant chemotherapy in gynaecological cancers – Implications for staging. *Best Practice & Research Clinical Obstetrics & Gynaecology*. 2015; 29(6): 790–801. doi:10.1016/j.bpobgyn.2015.02.008
72. Bristow R., Giuntoli R., Pannu H., Schulick R., Fishman E. and Wahl R. Combined PET/CT for detecting recurrent ovarian cancer limited to retroperitoneal lymph nodes. *Gynecologic Oncology*. 2005; 99: 294–300. doi: 10.1016/j.ygyno.2005.06.019
73. Queiroz M. A., Kubik-Huch R. A., Hauser N., Freiwald-Chilla B., von Schulthess G., Froehlich, J. M. et al. PET/MRI and PET/CT in advanced gynaecological tumours: initial experience and comparison. *Eur Radiol*. 2015; 25(8): 2222–2230. doi:10.1007/s00330-015-3657-8
74. Partovi S, Kohan A, Rubbert C, Vercher-Conejero J.L., Gaeta C., Yuh R. et al. Clinical oncologic applications of PET/MRI: a new horizon. *Am J Nucl Med Mol Imaging*. 2014; 4:202–12.
75. Wright A. A., Bohlke K., Armstrong D. K., Bookman M. A., Cliby W. A., Coleman R. L. et al. Neoadjuvant chemotherapy for newly diagnosed, advanced ovarian cancer: Society of Gynecologic Oncology and American Society of Clinical Oncology Clinical Practice Guideline. *Gynecologic Oncology*. 2016; 143(1): 3–15. doi:10.1016/j.ygyno.2016.05.022
76. Chang S.-J., Hodeib M., Chang J., Bristow R. E. Survival impact of complete cytoreduction to no gross residual disease for advanced-stage ovarian cancer: A meta-analysis. *Gynecol Oncol*. 2013; 130(3): 493–498. doi:10.1016/j.ygyno.2013.05.040

77. Wallace S., Kumar, A. Mc Gree M., Weaver, A., Mariani A., Langstraat C. et al. Efforts at maximal cytoreduction improve survival in ovarian cancer patients, even when complete gross resection is not feasible. *Gynecol Oncol.* 2017; 145(1): 21–26. doi:10.1016/j.ygyno.2017.01.029
78. Choi C., Kim W. Y., Lee D. H., Oh S. S. Cytoreduction of bulky para-aortic lymphadenopathy from metastatic ovarian cancer. *Gynecol Oncol.* 2017; 147(1): 188. doi:10.1016/j.ygyno.2017.07.133
79. Sioulas V. D., Schiavone M. B., Kadouri D., Zivanovic O., Roche K. L., O’Cearbhaill R. et al. Optimal primary management of bulky stage IIIc ovarian, fallopian tube and peritoneal carcinoma: Are the only options complete gross resection at primary debulking surgery or neoadjuvant chemotherapy? *Gynecol Oncol.* 2017; 145(1): 15–20. doi:10.1016/j.ygyno.2017.02.023
80. Vermeulen C. K. M., Tadesse W., Timmermans M., Kruitwagen R. F. P. M., Walsh T. Only complete tumour resection after neoadjuvant chemotherapy offers benefit over suboptimal debulking in advanced ovarian cancer. *European Journal of Obstetrics & Gynecology and Reproductive Biology.* 2017; 219: 100–105. doi:10.1016/j.ejogrb.2017.10.019
81. Liu J. Should neoadjuvant chemotherapy be preferred to an alternative treatment for advanced ovarian cancer: Comparison of neoadjuvant chemotherapy followed by interval debulking surgery and primary debulking surgery in patients with advanced ovarian cancer. *Gynecol Oncol.* 2015; 137: 176. doi:10.1016/j.ygyno.2015.01.441
82. Conrad L. B., Schmidt S., Bailey A. A., Carlson M., Kehoe S., Richardson D. et al. Patients with Sarcopenia Benefit from Neoadjuvant Chemotherapy in Advanced Ovarian Cancer. *Gynecol Oncol.* 2017; 147(1): 226. doi:10.1016/j.ygyno.2017.07.094
83. Kessous R., Laskov I., Abitbol J., Bitharas J., Yasmeen A., Salvador S., Lau S., Gotlieb W. H. Clinical outcome of neoadjuvant chemotherapy for advanced ovarian cancer. *Gynecol Oncol.* 2017; 144(3): 474–479. doi: 10.1016/j.ygyno.2016.12.017
84. Vergote I., Trope C.G., Amant F., Kristensen G. B., Ehlen T., Johnson N. et al. Neoadjuvant chemotherapy or primary surgery in stage IIIc or IV ovarian cancer. *N. Engl. J. Med.* 2010; 363(10): 943–953. doi: 10.1056/NEJMoa0908806.
85. Kehoe S., Hook J., Nankivell M., Jayson G. C., Kitchen H., Lopes T. et al. Primary chemotherapy versus primary surgery for newly diagnosed advanced ovarian cancer (CHORUS): an open-label, randomised, controlled, non-inferiority trial. *The Lancet.* 2015; 386(9990): 249–257. doi:10.1016/s0140-6736(14)62223-6
86. Available at: <https://clinicaltrials.gov/show/NCT02828618>
87. Rustin G., Vergote I., Eisenhauer E., Pujade-Lauraine E., Quinn M., Thigpen T. et al. Definitions for Response and Progression in Ovarian Cancer Clinical Trials Incorporating RECIST 1.1 and CA 125 Agreed by the Gynecological Cancer Inter-group (GCIg). *International Journal of Gynecological Cancer.* 2011; 21(2): 419–423. doi:10.1097/IGC.0b013e3182070f17
88. Rockall A., Munari A., Avril N. New ways of assessing ovarian cancer response: metabolic imaging and beyond. *Cancer Imaging.* 2012; 12(2): 310–314. doi:10.1102/1470-7330.2012.9004
89. Mahajan A., Sable N., Popat P., Bhargava P., Gangadhar K., Thakur M. et al. Magnetic Resonance Imaging of Gynecological Malignancies: Role in Personalized Management. *Seminars in Ultrasound, CT and MRI.* 2017; 38(3): 231–268. doi:10.1053/j.sult.2016.11.005
90. Forstner R., Meissnitzer M., Schlattau A., Spencer J. MRI in ovarian cancer. *Imaging in Medicine.* 2012; 4(1): 59–75. doi:10.2217/IM.11.69
91. Marcus C., Maxwell G., Darcy K., Hamilton C., McGuire W. Current Approaches and Challenges in Managing and Monitoring Treatment Response in Ovarian Cancer. *Journal of Cancer.* 2014; 5(1): 25–30. doi:10.7150/jca.7810
92. Kyriazi S., Collins D., Messiou C., Pennert K., Davidson R., Giles, S. et al. Metastatic Ovarian and Primary Peritoneal Cancer: Assessing Chemotherapy Response with Diffusion-weighted MR Imaging—Value of Histogram Analysis of Apparent Diffusion Coefficients. *Radiology.* 2011; 261(1): 182–192. doi:10.1148/radiol.11110577
93. Sala E., Kataoka M., Priest A., Gill A., McLean M., Joubert I. et al. Advanced Ovarian Cancer: Multiparametric MR Imaging Demonstrates Response- and Metastasis-specific Effects. *Radiology.* 2012; 263(1): 149–159. doi:10.1148/radiol.11110175
94. Gu P., Pan L., Wu S., Sun L., Huang G. CA 125, PET alone, PET-CT, CT and MRI in diagnosing recurrent ovarian carcinoma: a systematic review and meta-analysis. *Eur J Radiol.* 2009; 71(1): 164–174. doi:10.1016/j.ejrad.2008.02.019
95. Suppiah S., Chang W., Hassan H., Kaewput C., Asri A., Saad F. et al. Systematic review on the accuracy of positron emission tomography/computed tomography and positron emission tomography/magnetic resonance imaging in the management of ovarian cancer: is functional information really needed? *World J Nucl Med.* 2017; 16(3): 176–185. doi:10.4103/wjnm.WJNM_31_17
96. Michielsen K., Vergote I., Dresen R., Op de Beeck K., Vanslebrouck R., Amant F. et al. Whole body diffusion-weighted magnetic resonance imaging in the diagnosis of recurrent ovarian cancer: a clinical feasibility study. *Br J Radiol.* 2016; 89(1067): 20160468. doi:10.1259/bjr.20160468
97. Bakhtiozin R., Safiullin R. Whole-body diffusion-weighted imaging in diagnosis and monitoring of malignant neoplasm treatment. *REJR.* 2011; 1(2): 13–18. 10.
98. Rubtsova N., Novikova E., Sychenkova I. Current possibilities of magnetic – resonance imaging in detection of ovarian cancer. *Research’n Practical Medicine Journal.* 2017; 4(1): 40–48 (in Russian). doi:10.17709/2409-2231-2017-4-1-5
99. Fournier L., Bennani S., Bats A., Rousseau C., Bensaid C., Lecuru F. et al. Pitfalls in Imaging For Advanced Ovarian Cancer. *Seminars in Roentgenology.* 2015; 50(4): 284–293. doi:10.1053/j.ro.2015.08.005
100. Michielsen K., Dresen R., Vanslebrouck R., Keyzer F., Amant F., Mussen E. et al. Diagnostic value of whole body diffusion-weighted MRI compared to computed tomography for preoperative assessment of patients suspected for ovarian cancer. *European Journal of Cancer.* 2017; 83: 88–98. doi:10.1016/j.ejca.2017.06.010.